

DBS in età evolutiva. Esperienza iniziale (2007-2008) e problematiche in ambito pediatrico.

Flavio Giordano^{*}, Federico Mussa^{*}, Lorenzo Genitori^{*}
Michele A. Cavallo [#], Rocco Quattrale[#]
Roberta Battini[^], Andrea Guzzetta[^], Giovanni Cioni[^]

^{*}Neurochirurgia -Ospedale Pediatrico “Anna Meyer” - Firenze
Coordinamento Regionale Firenze – Siena – Pisa
[#]Neurochirurgia e Neurologia – Arcispedale S.Anna - Ferrara
[^] IRCCS “Stella Maris” – Calambrone

General Surgical Series (DBS)

Period of observation 2004-2008

21 adult cases (mean age 52 yrs)

+ 2 adolescent cases (mean age 17 yrs)

23 Deep Brain Stimulations procedures

17 Parkinson disease (STN)

4 Essential tremor (VIM)

2 Dystono-discinetic syndromes

Surgical Series in Dystonia

Period of observation 2007-2008

2 adolescent cases (mean 17 yrs)

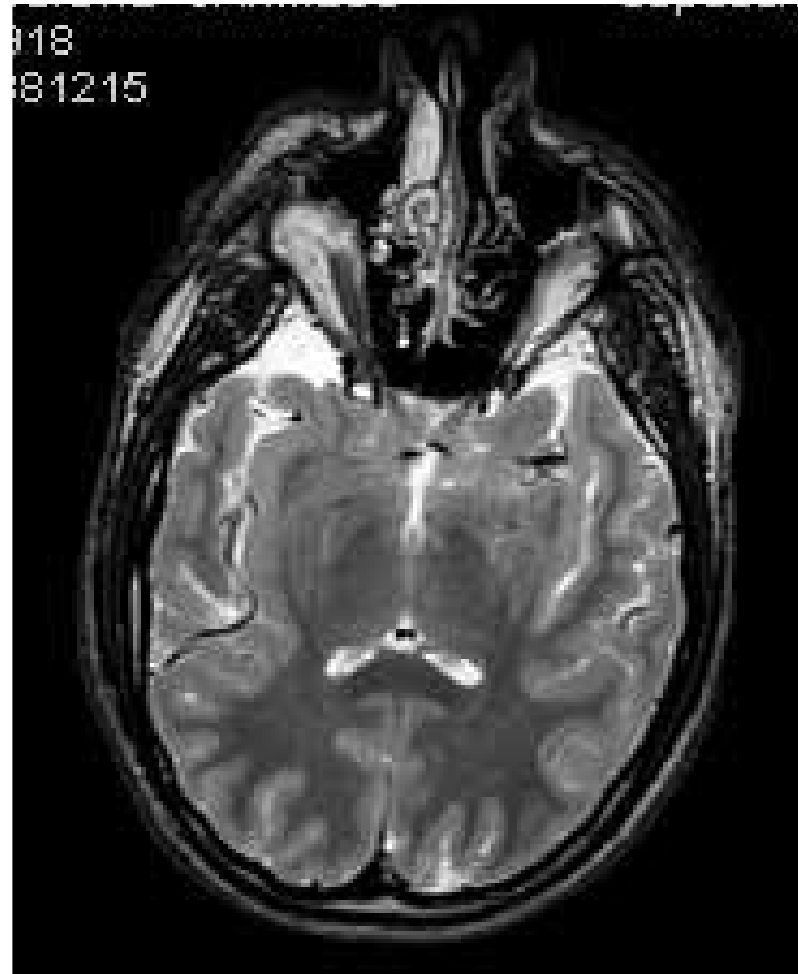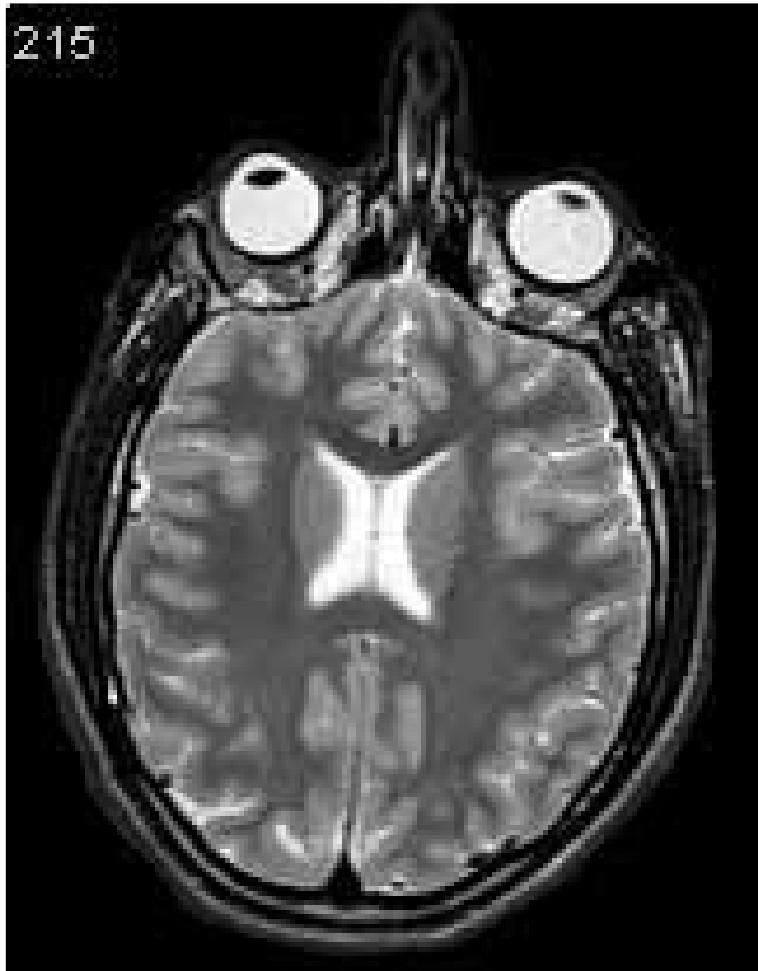
Mean follow-up 7.5 months (7 – 8 mos)

2 Deep Brain Stimulations procedures

1 Idiopathic Primary Generalized dystonia (Gpi)

1 Secondary post-traumatic dystonia (VIM)

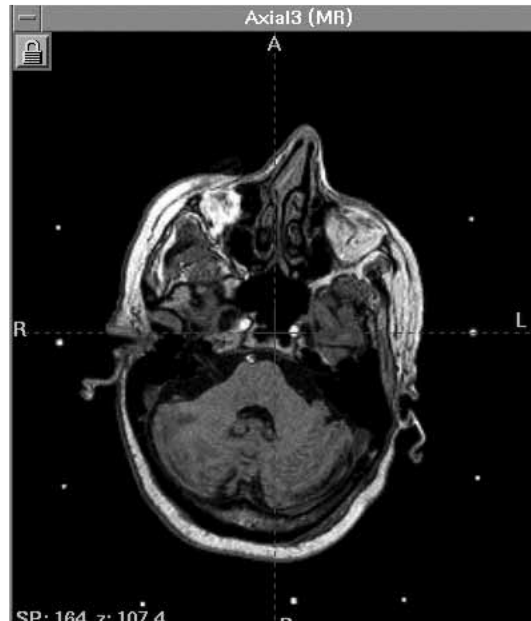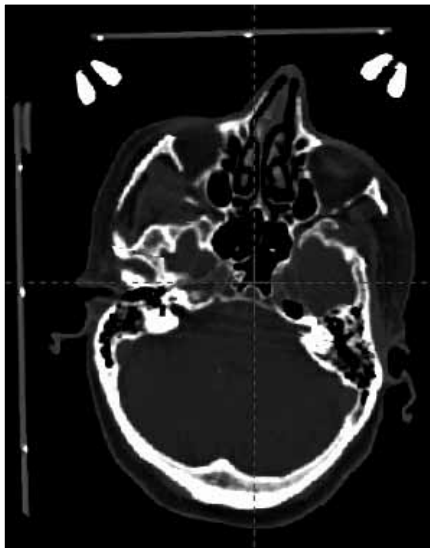
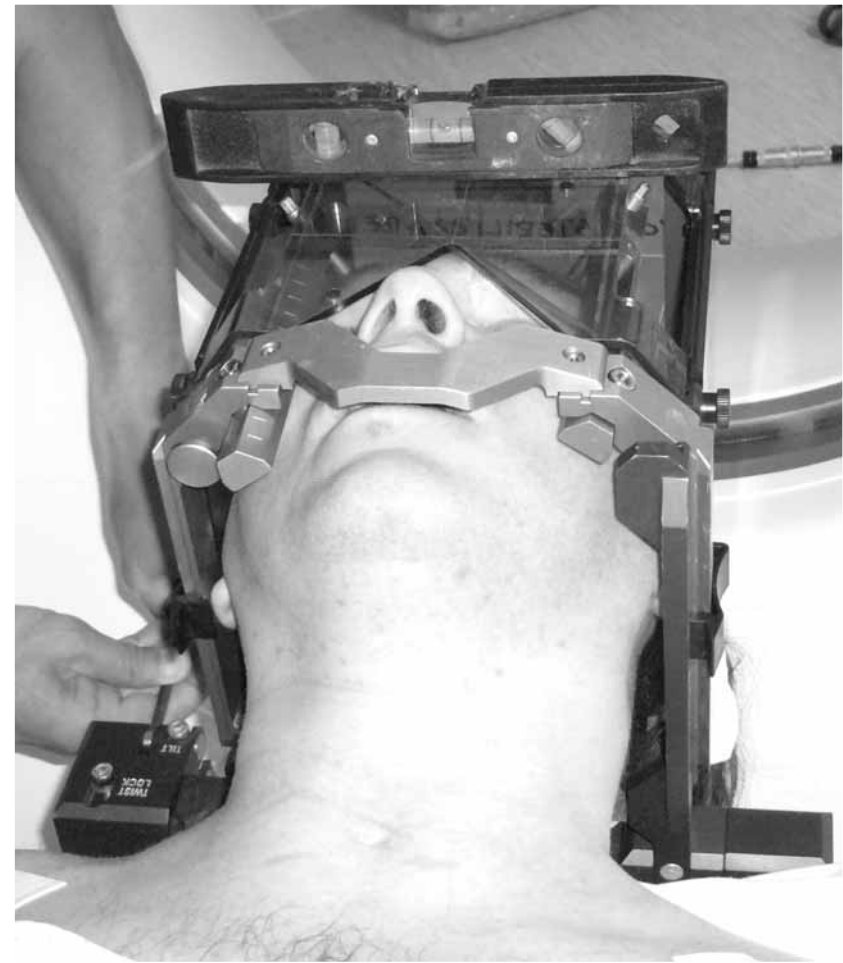
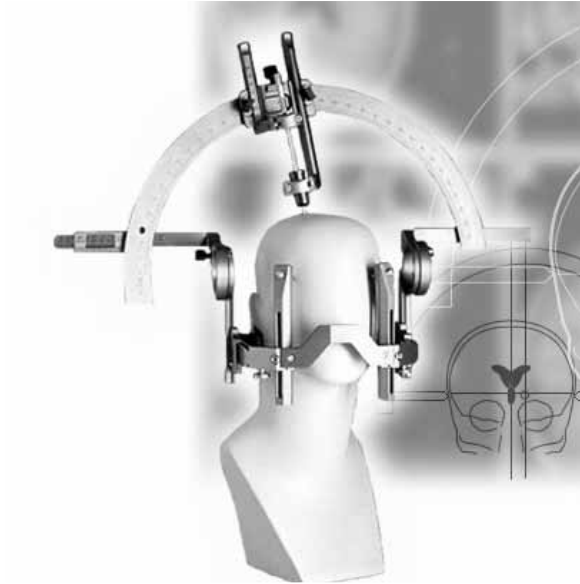Since 1995 to 2008, 9/58 (15.5%) ITB implantations for secondary dystonia



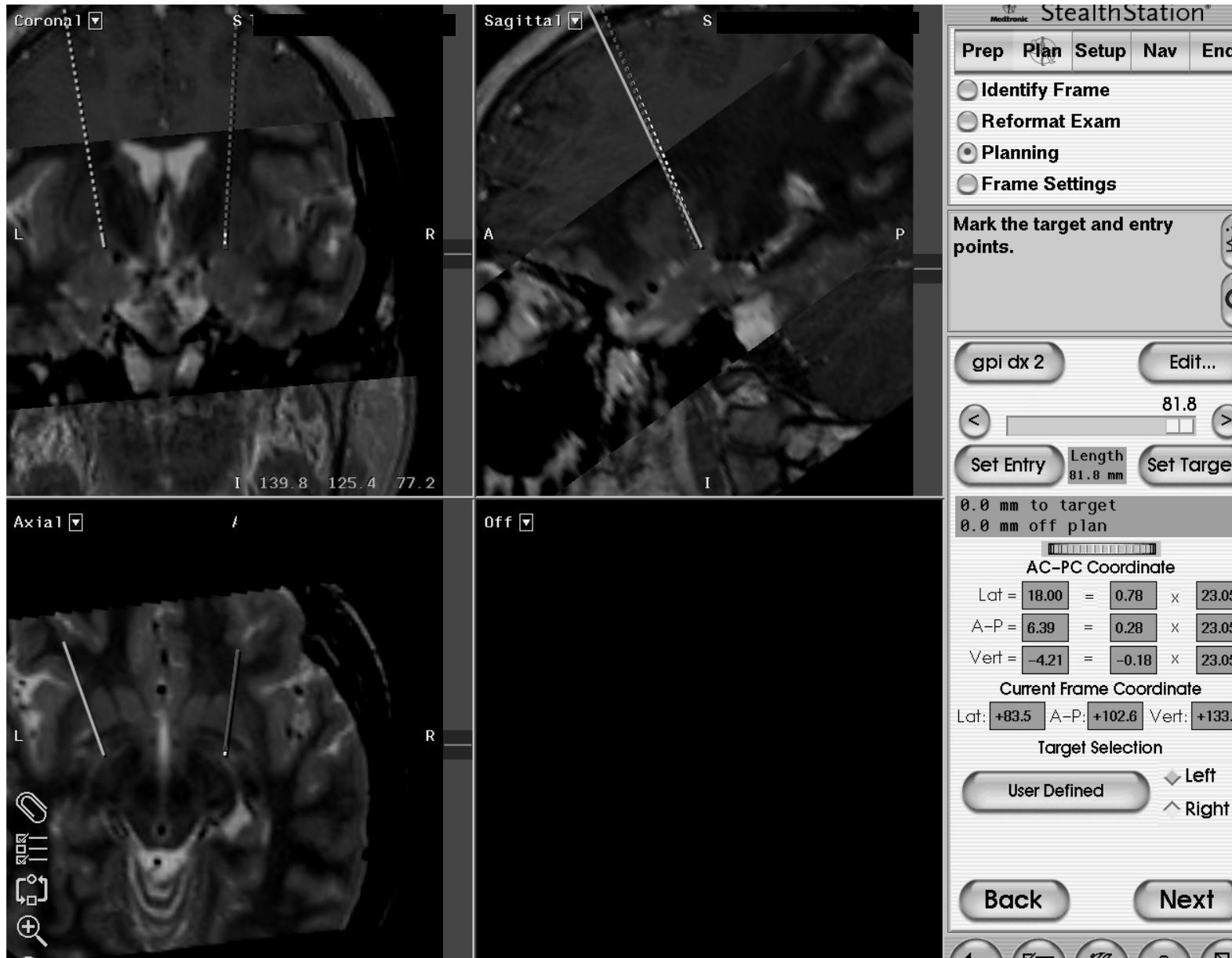
Case #1

TC, 16 yrs, male; early onset generalized idiopathic dystonia
DYT-1 mutation negative

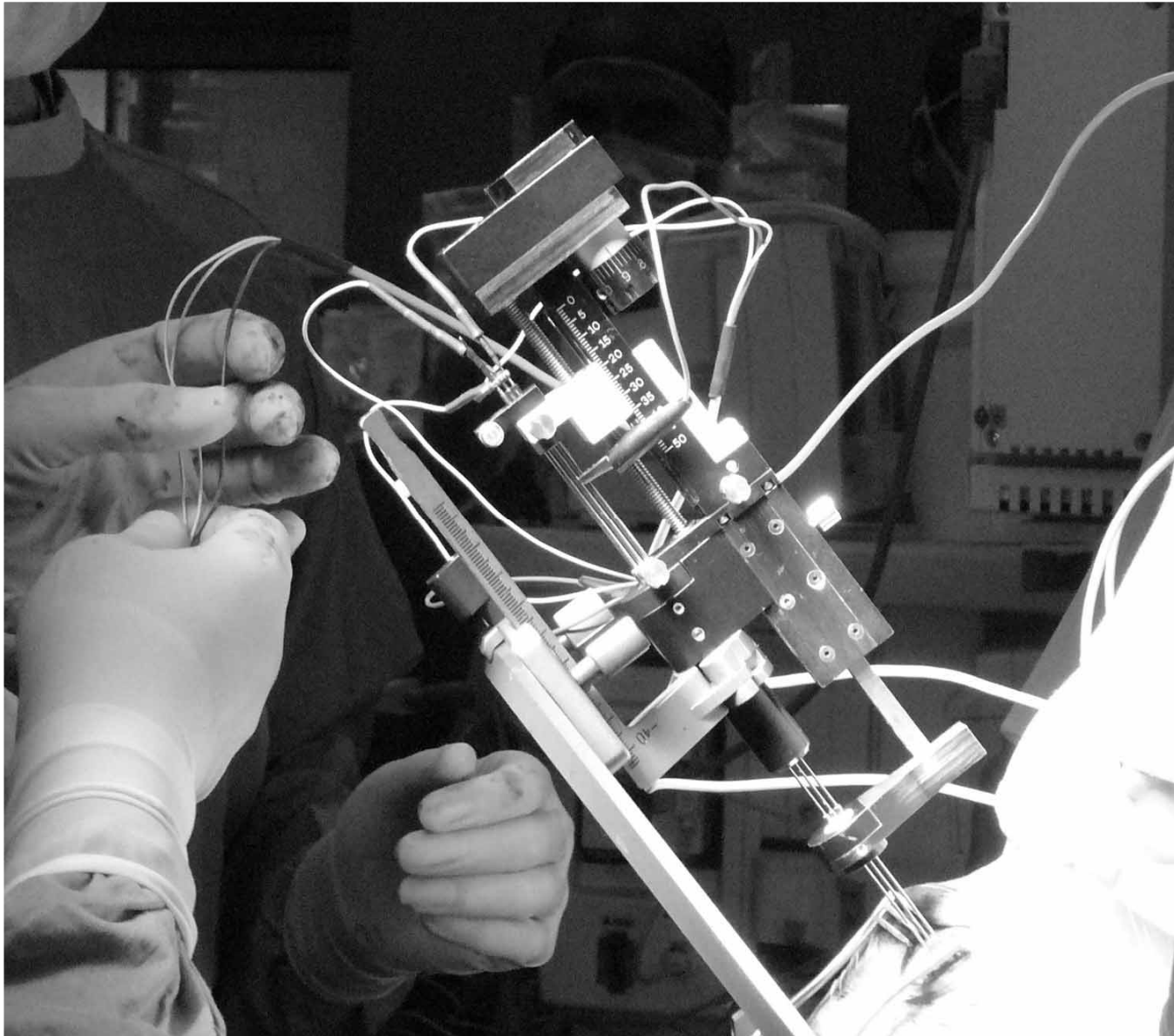
Not responsive to L-DOPA



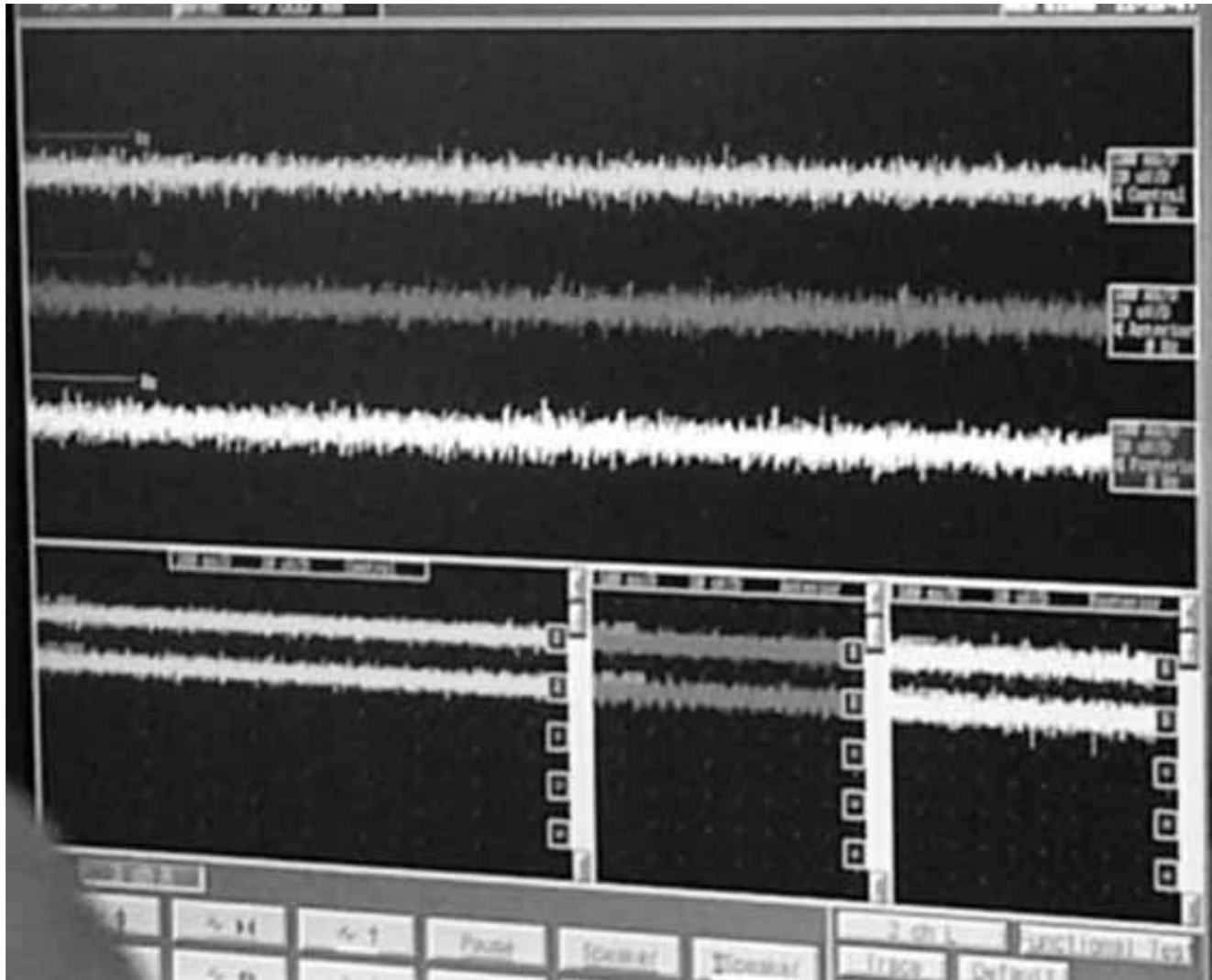
1) Acquisition with
Leksell frame




2) trajectory planning with Framelink



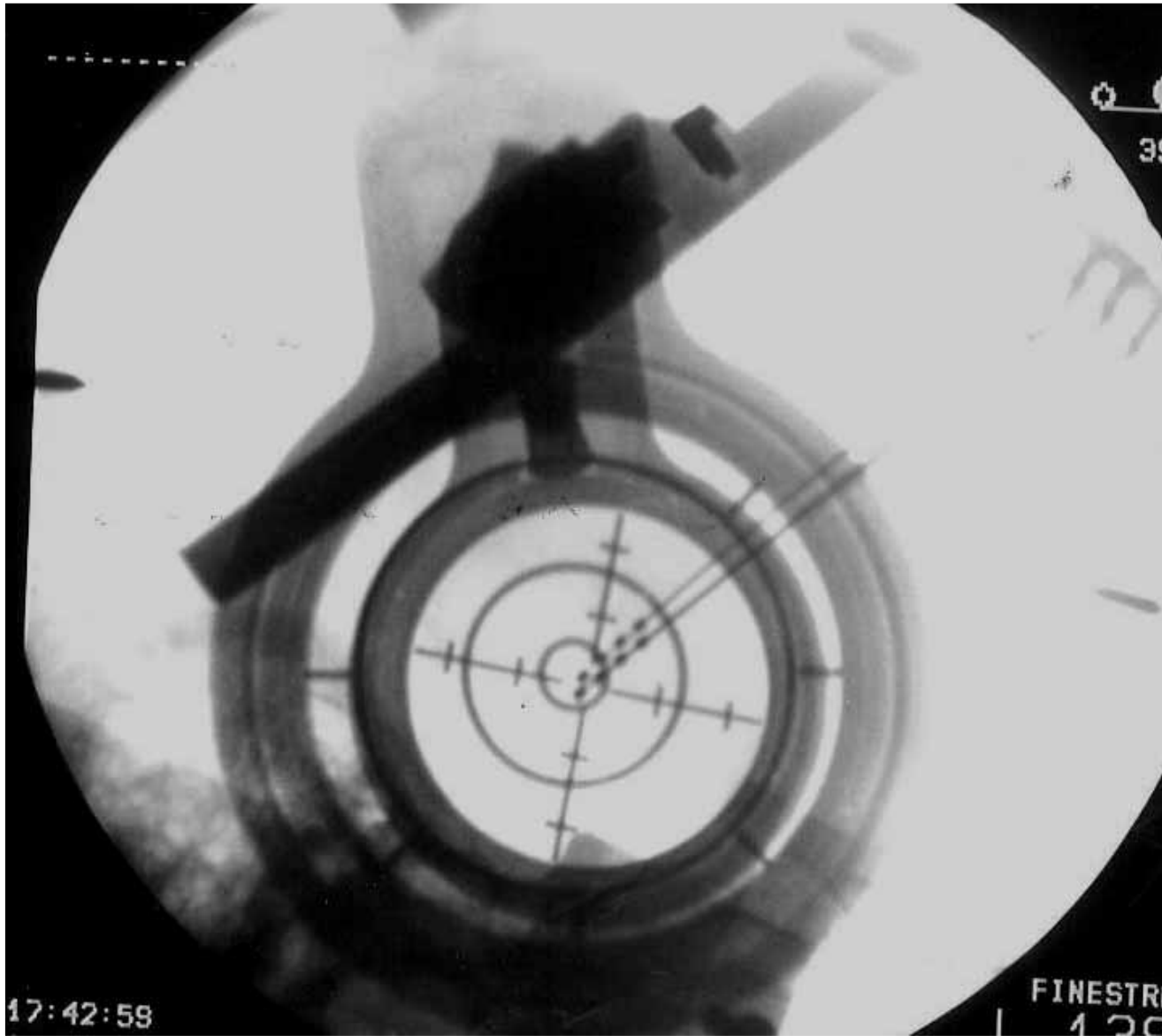3) Targeting in local anesthesia



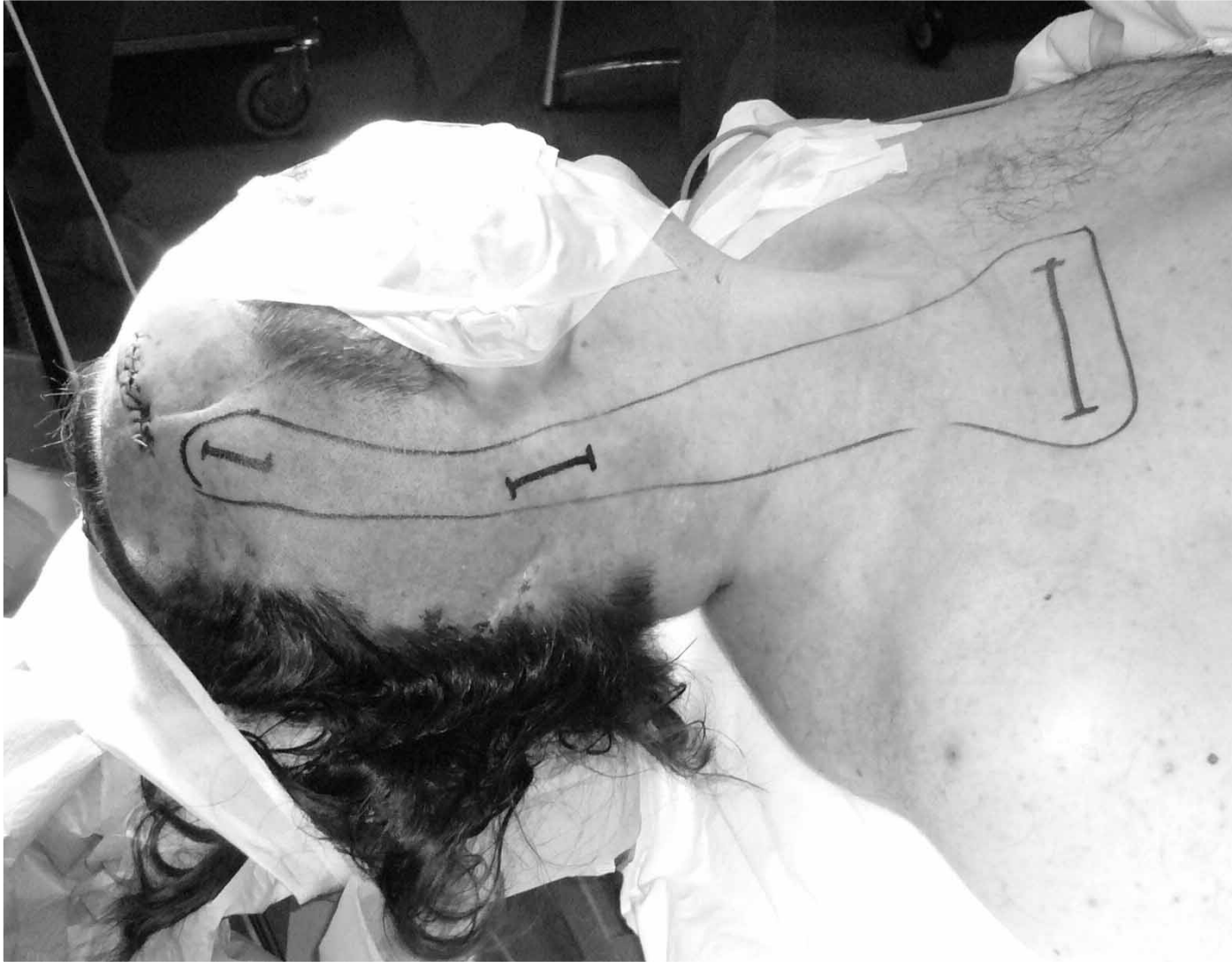4) targeting + MicroElectrode Recording and stimulation (MER)



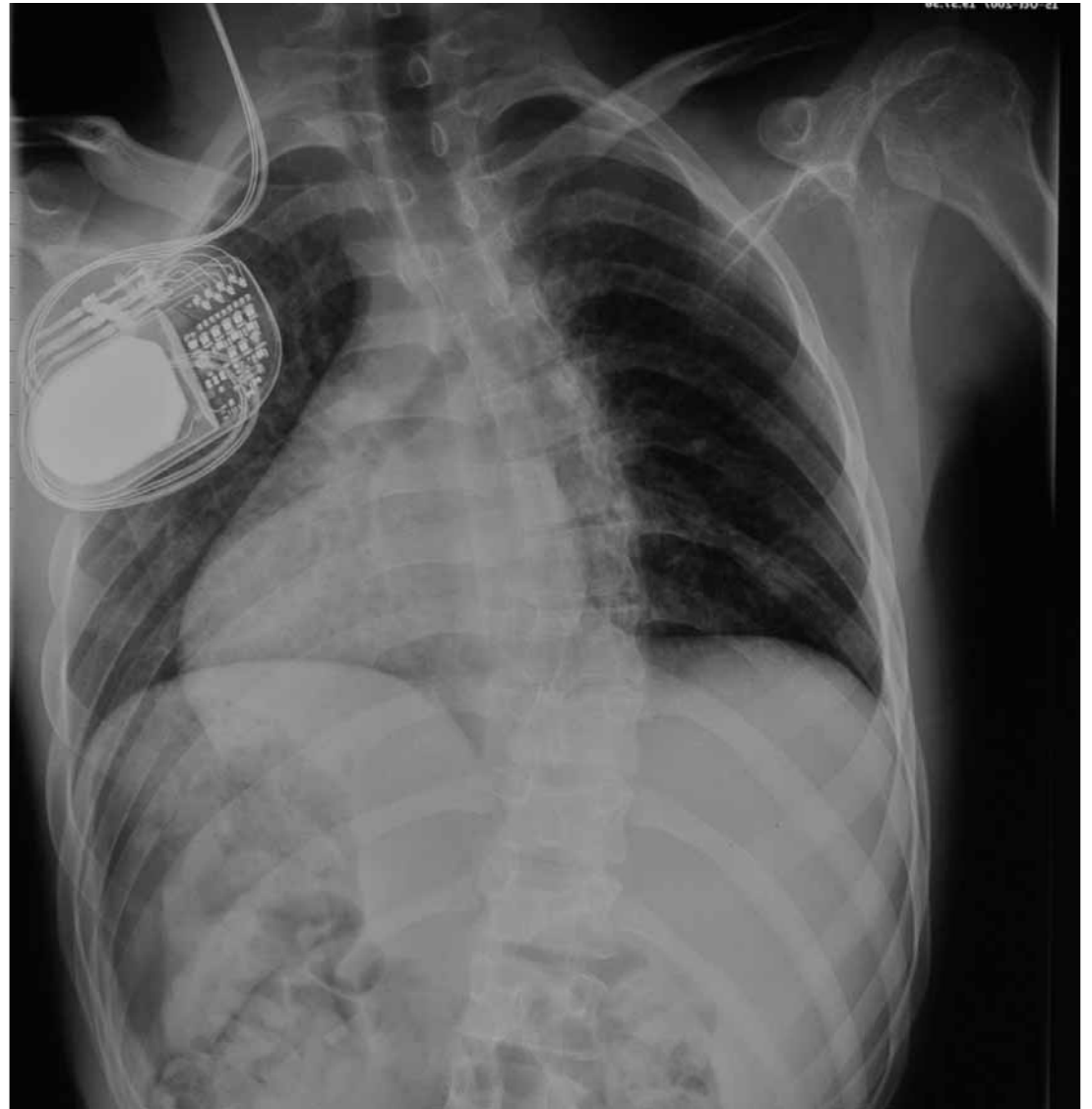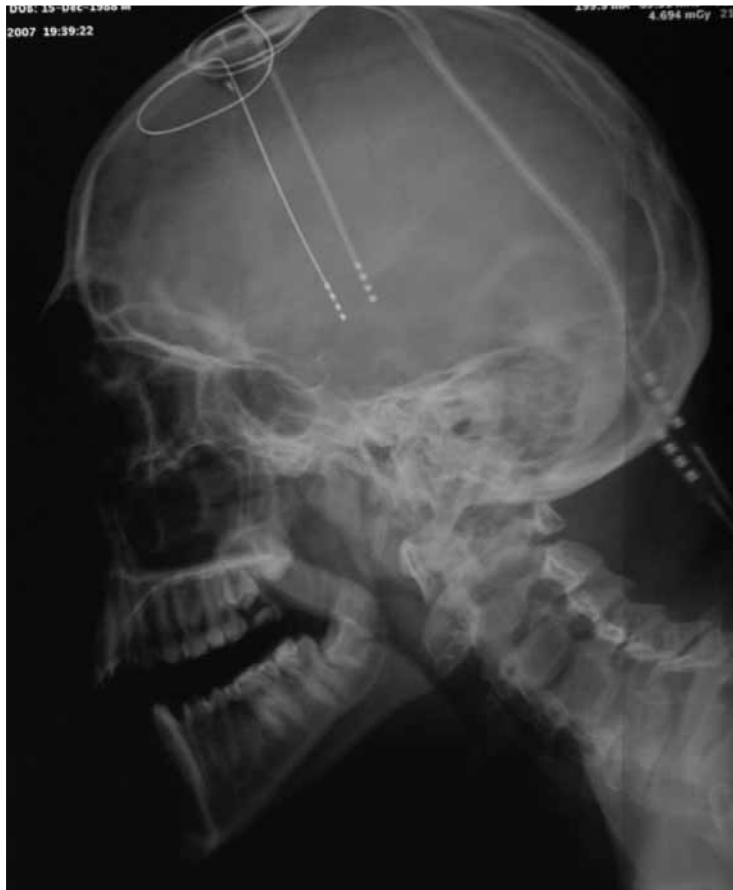5) macroelectrode
placement

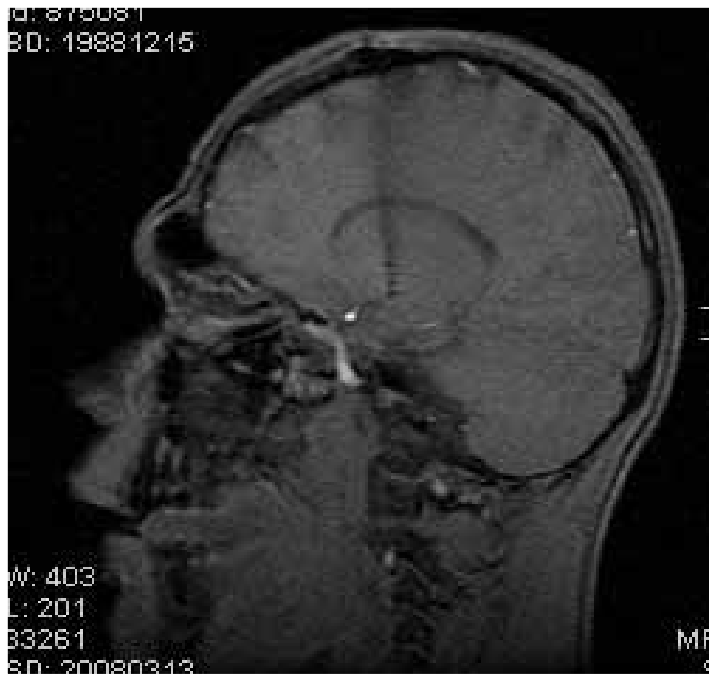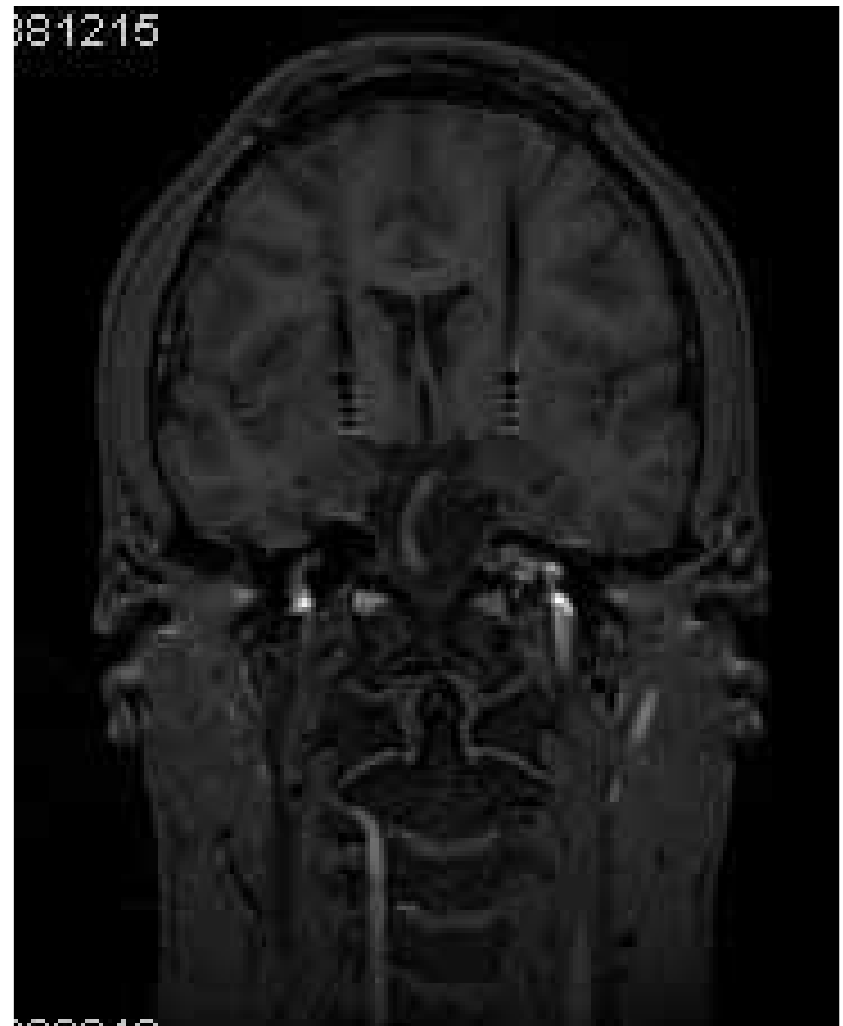
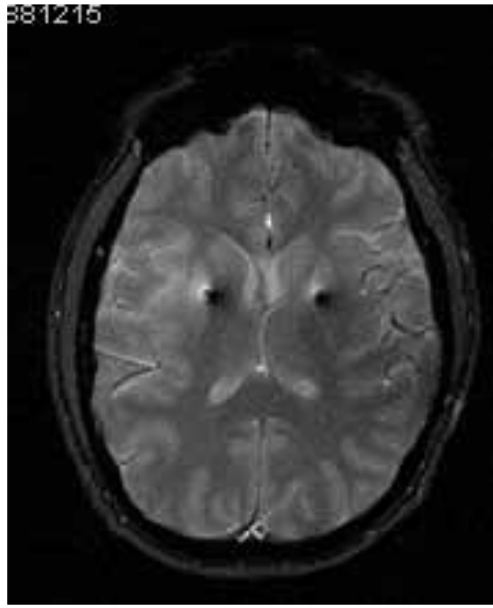
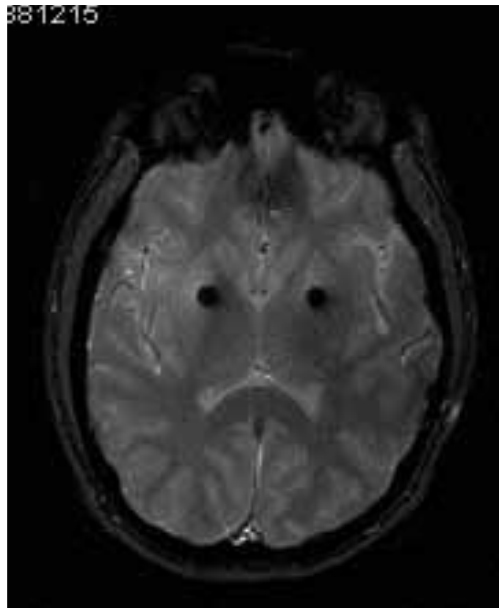


6) Intraoperative fluoroscopic control



7) Implantable Pulse Generator (IPG) insertion in the same day

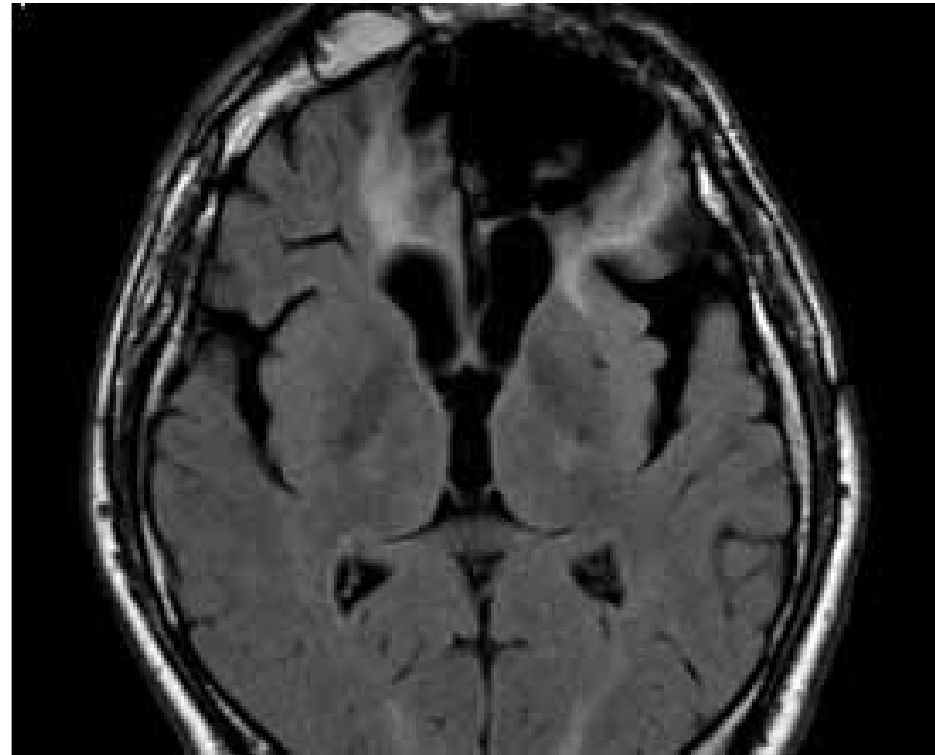
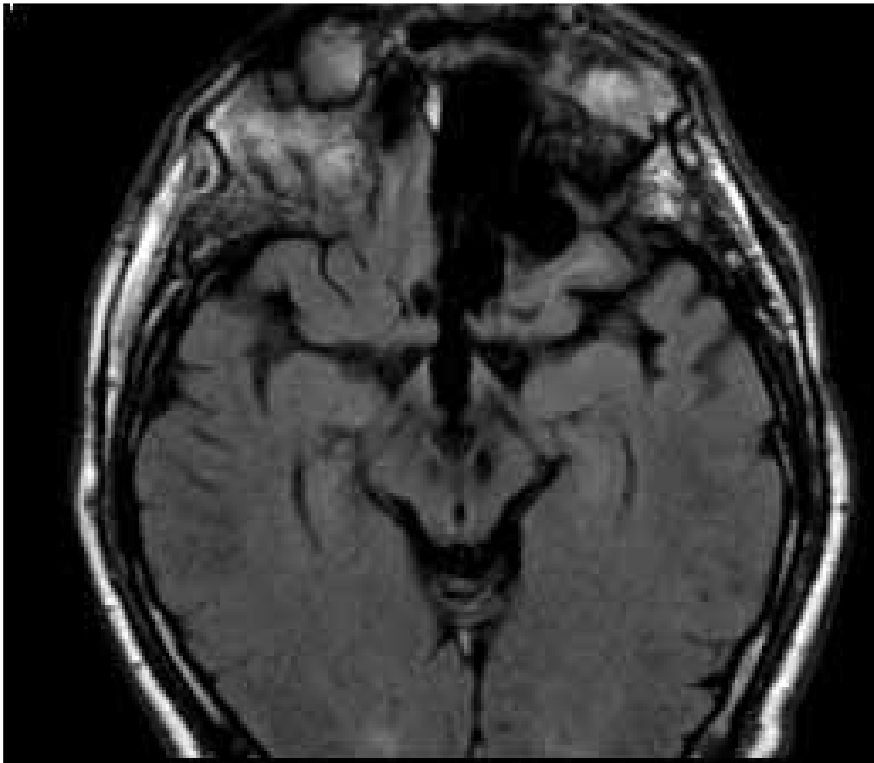




Post-op MR control

No surgical complications

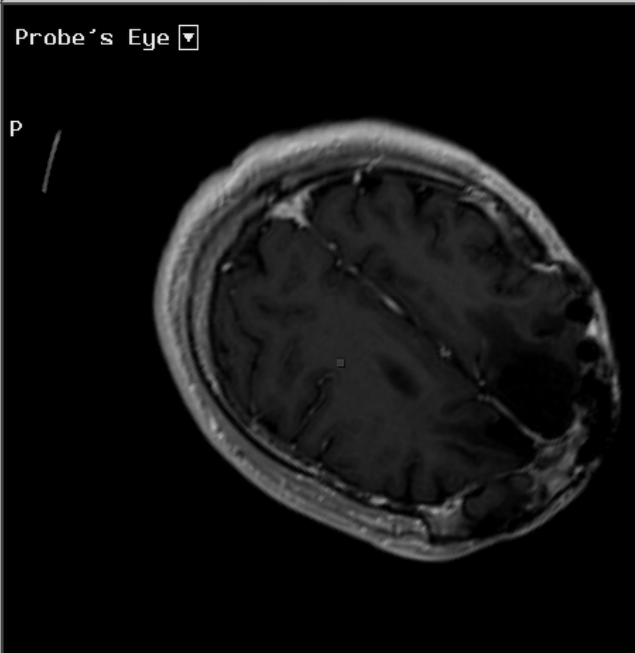
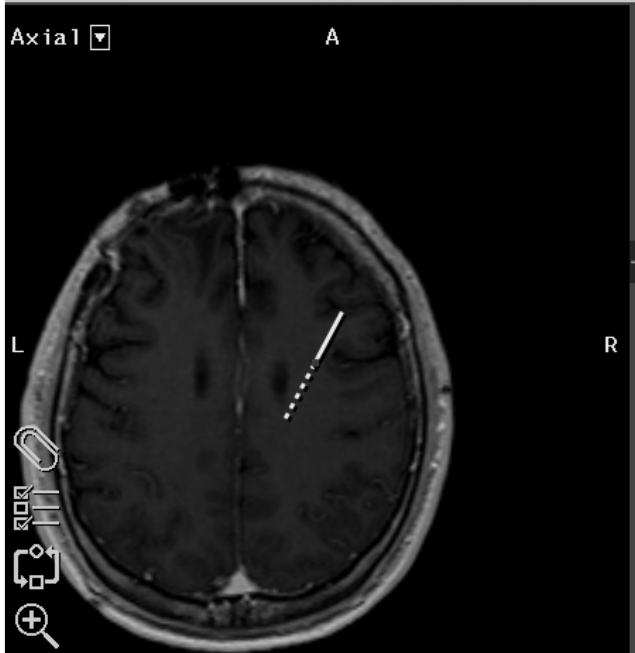
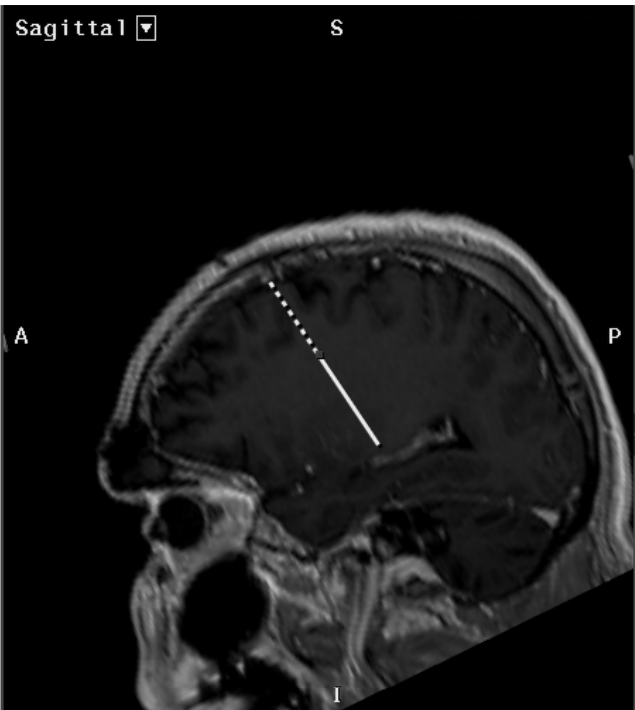
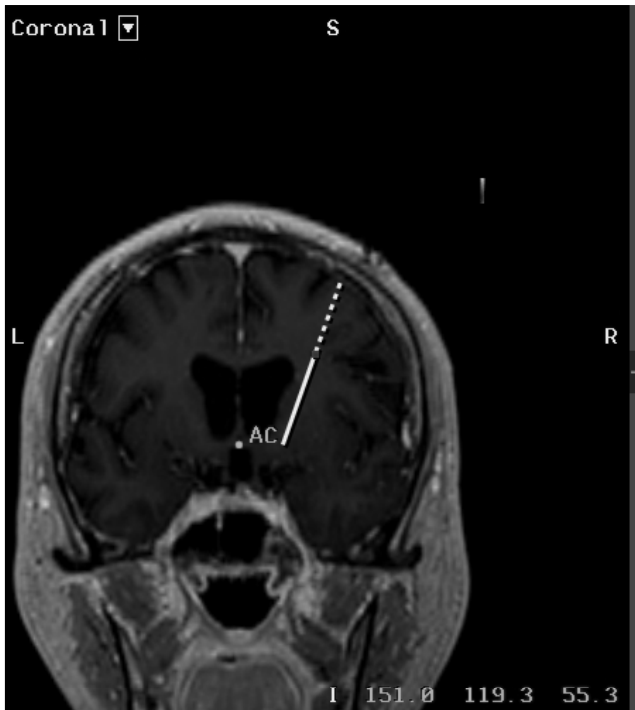
Correct macro-electrode position



Case #2

SR, 18 yrs, male; secondary dyskinetic-dystonic movement disorder with tremor; severe head injury 3 years before

Unable to solve any movement task



Medtronic **StealthStation[®]**

Prep Plan Setup Nav End

Identify Frame
 Reformat Exam
 Planning
 Frame Settings

Select a plan and read the frame settings.

vimright Edit...

36.9

Set Entry Length 79.8 mm Set Target

42.9 mm to target
0.0 mm off plan

Frame Settings

Lat (x): +81.8 +/- (x)

A-P (y): +90.5 +/- (y)

Vert (z): +115.1

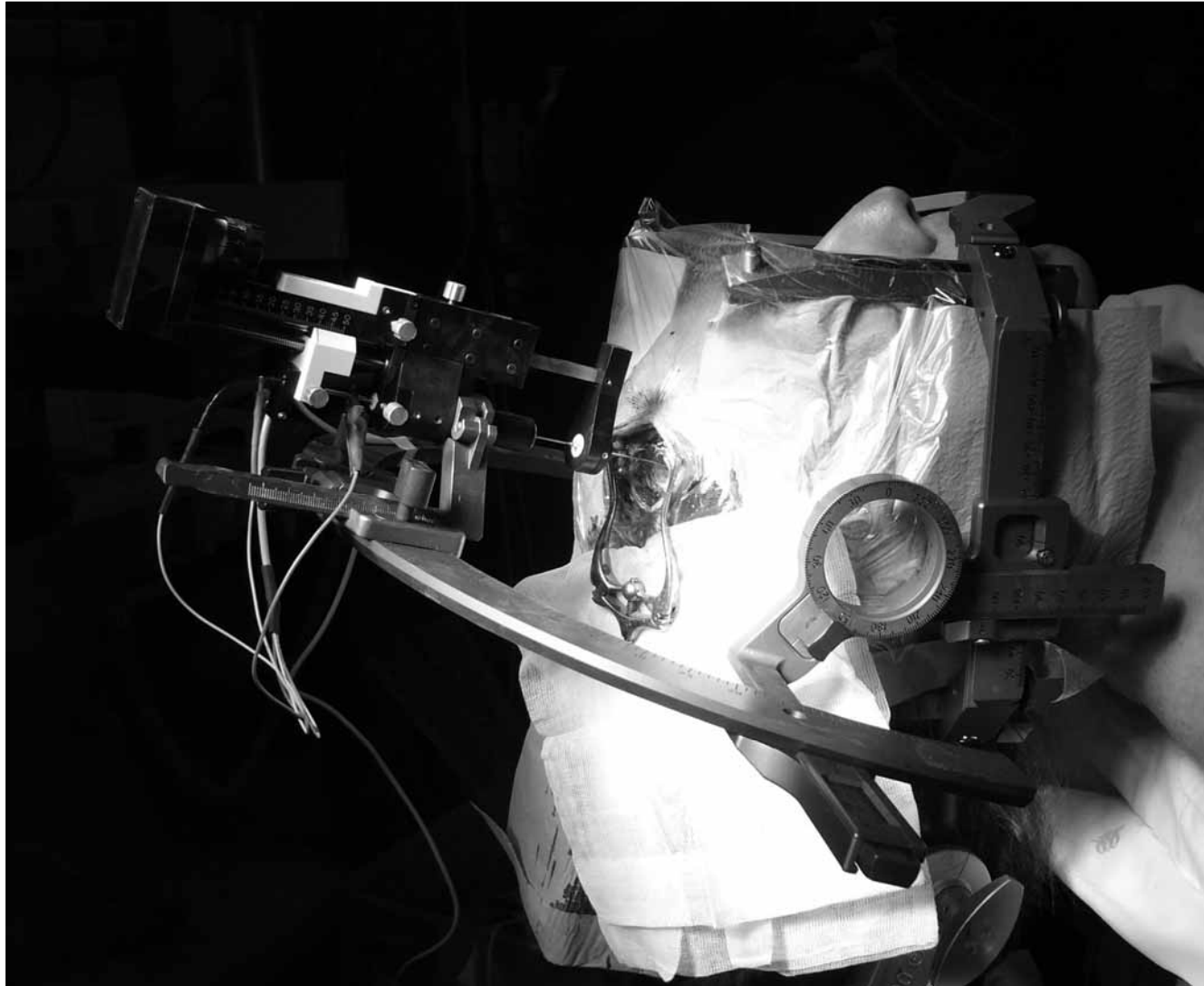
Ring: 73.8 New Track

Arc: 71.0

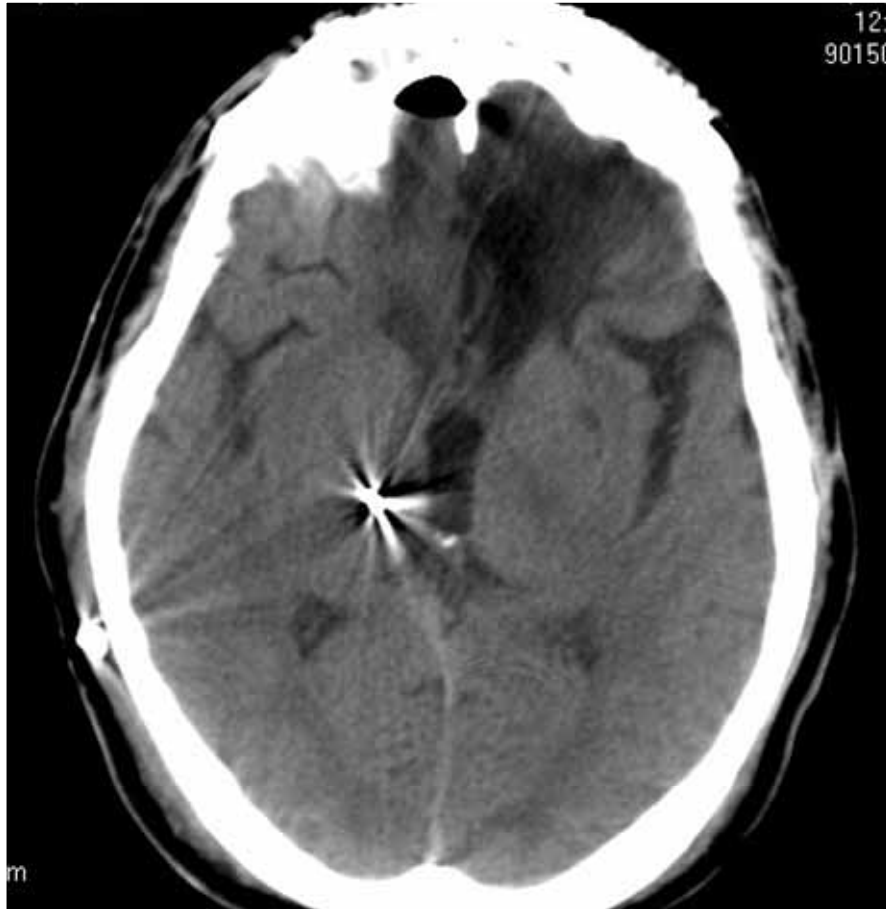Current Frame Coordinate

Lat: +67.9 A-P: +101.8 Vert: +76.1

Back Next



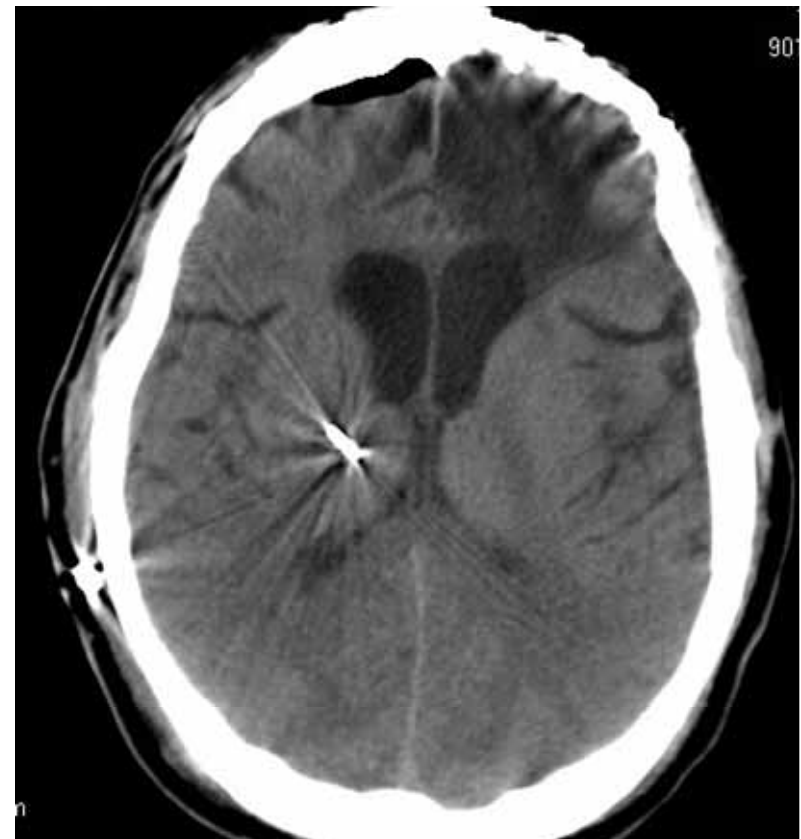Targeting and stimulation in local anesthesia



No surgical morbidity

....8 months later...

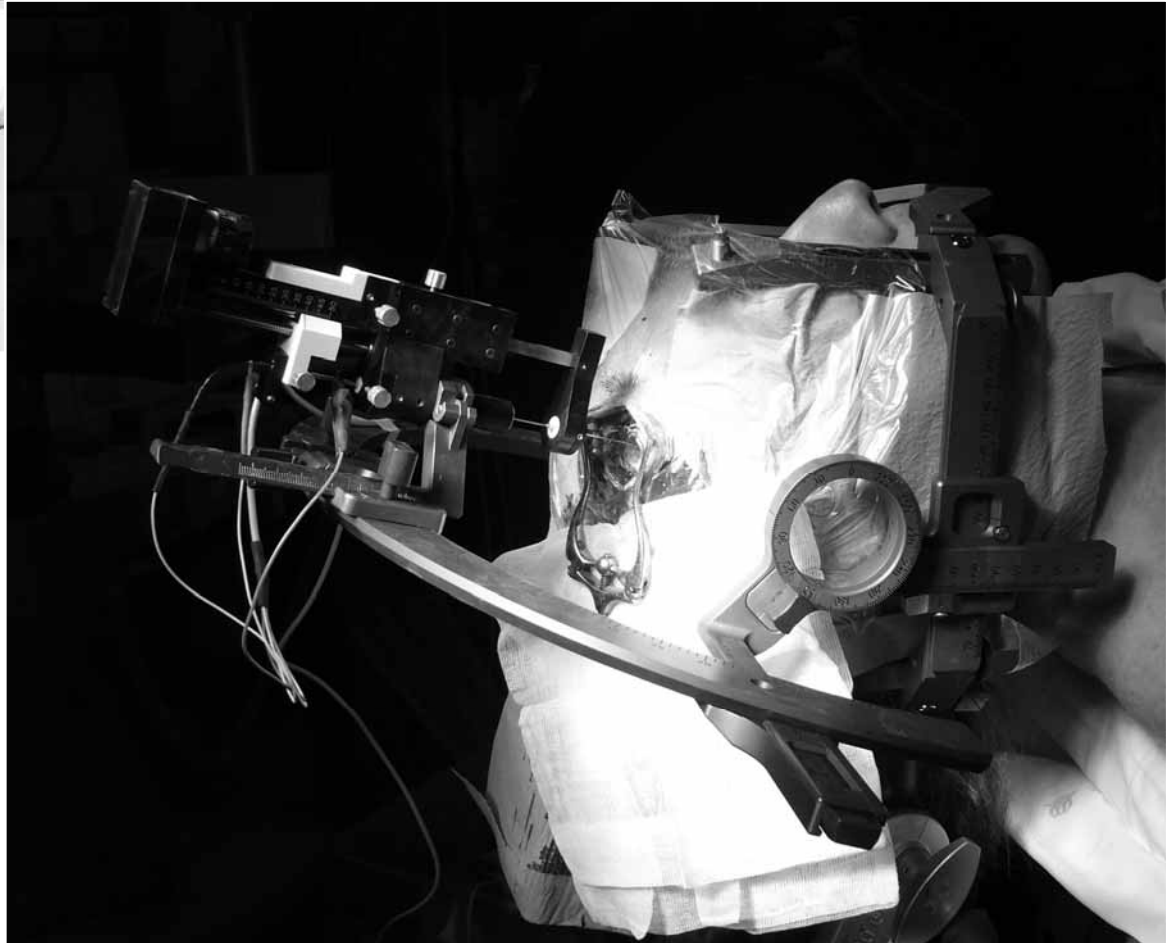
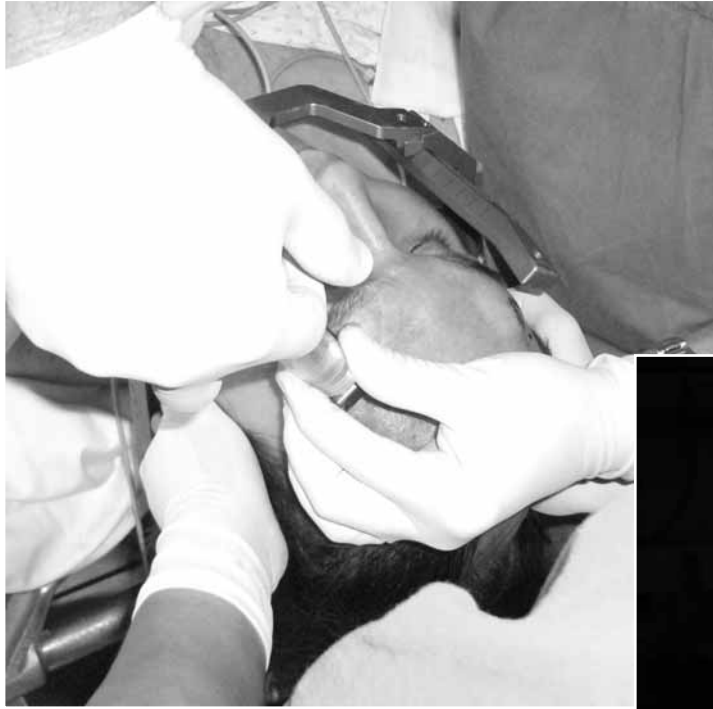20% improvement according to
BFMDRS score but able to use
the mouse-joystick

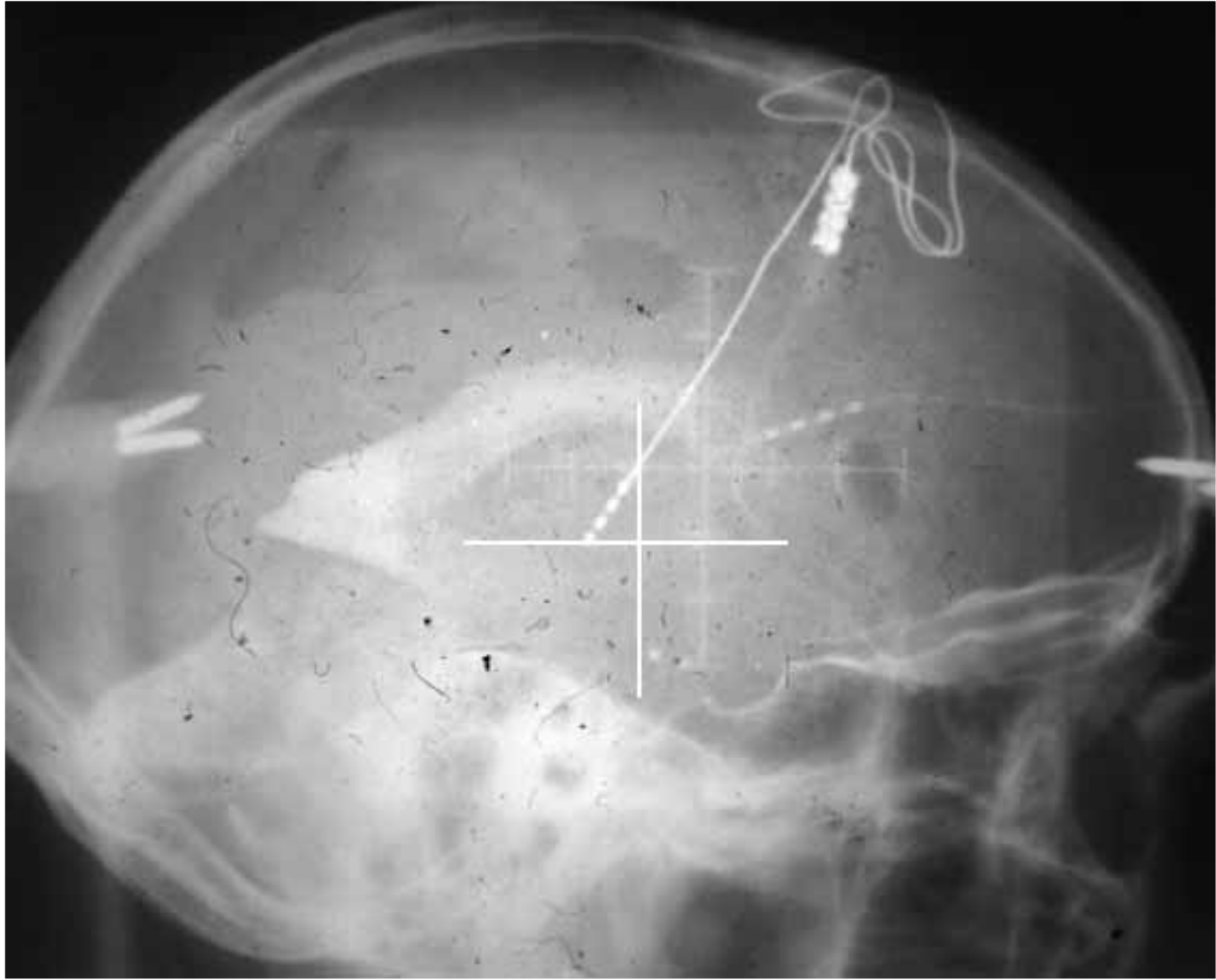


Problems in the Pediatric field

Surgical technique

- difficult or null collaborations during surgery (general anesthesia is required with ketamin + remifentanyl); local anesthesia from 11 yrs
- Beware of chronic subclinic infections (i.e. dental granuloma)
- stereotactic atlas planned for adults
- ventriculography and old techniques difficult to apply (CSF leakage, toxicity, fragile skull)





Problems in the Pediatric field

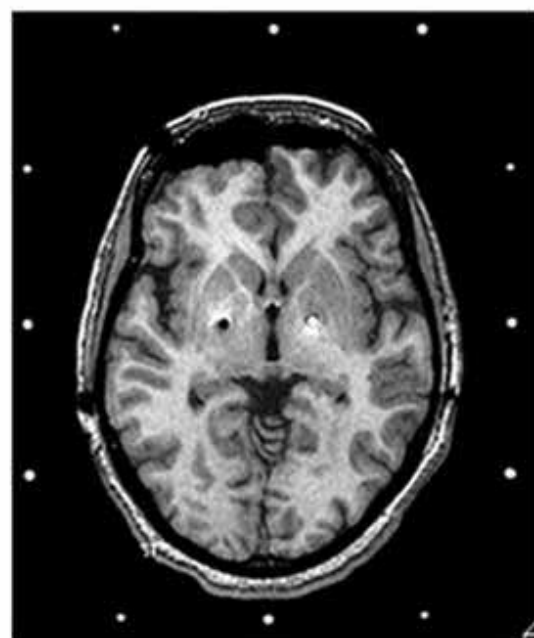
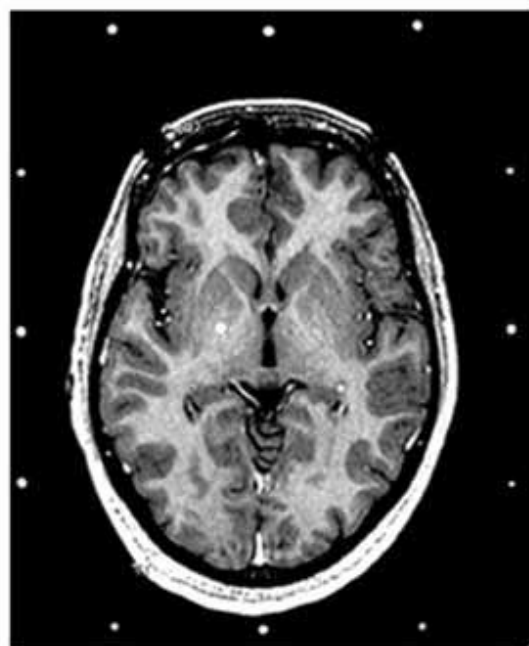
Surgical technique

- problem with stereotactic frame fixation to little children (2 – 4 yrs) (??)
- interest in new localization systems (Nex-Frame)
- anatomic targeting with stereotactic MR (Coubes' validated technique)
- the role of intra-op MR/CT control

Magnetic resonance imaging stereotactic target localization for deep brain stimulation in dystonic children

NATHALIE VAYSSIERE, PH.D., SIMONE HEMM, M.Sc., MICHEL ZANCA, M.D., PH.D.,
MARIE CHRISTINE PICOT, M.D., PH.D., ALAIN BONAFE, M.D., LAURA CIF, M.D.,
PHILIPPE FREREBEAU, M.D., PH.D., AND PHILIPPE COUBES, M.D., PH.D.

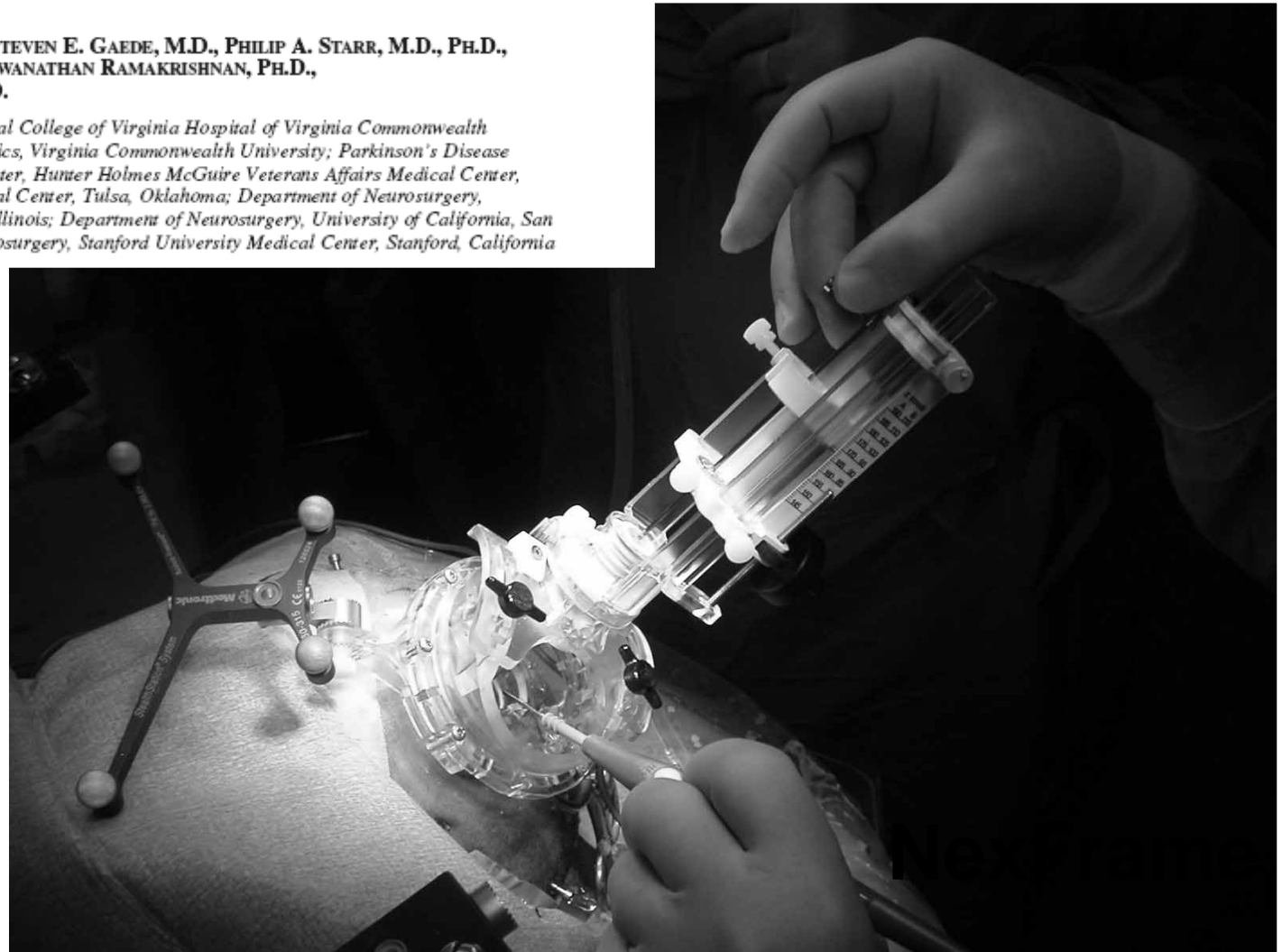
*Departments of Pediatric Neurosurgery (Research Group on Movement Disorders in Children),
Biophysics and Nuclear Medicine, Biostatistics, and Neuroradiology, University Hospital,
Montpellier, France*



Frameless stereotaxy using bone fiducial markers for deep brain stimulation

**KATHRYN L. HOLLOWAY, M.D., STEVEN E. GAEDE, M.D., PHILIP A. STARR, M.D., PH.D.,
JOSHUA M. ROSENOW, M.D., VISWANATHAN RAMAKRISHNAN, PH.D.,
AND JAIMIE M. HENDERSON, M.D.**

Department of Neurosurgery, Medical College of Virginia Hospital of Virginia Commonwealth University; Department of Biostatistics, Virginia Commonwealth University; Parkinson's Disease Research, Education & Clinical Center, Hunter Holmes McGuire Veterans Affairs Medical Center, Richmond, Virginia; St. John Medical Center, Tulsa, Oklahoma; Department of Neurosurgery, Northwestern University, Chicago, Illinois; Department of Neurosurgery, University of California, San Francisco; and Department of Neurosurgery, Stanford University Medical Center, Stanford, California



1: [Parkinsonism Relat Disord.](#) 2008 Mar 5. [Epub ahead of print]

Accuracy of stereotactic electrode placement in deep brain stimulation by intraoperative computed tomography.

Fiegele T, Feuchtner G, Sohm F, Bauer R, Anton JV, Gotwald T, Twerdy K, Eisner W.

Department of Neurosurgery, Innsbruck Medical University, Anichstrasse 35, 6020 Innsbruck, Austria.

The purpose of this study was to evaluate the accuracy of stereotactic electrode placement in patients undergoing deep brain stimulation by using pre- and postoperative computed tomography (CT). Twenty-three patients with movement disorders (Parkinson's disease (n=7), tremor (n=9), dystonia (n=7)) treated with bilateral deep brain stimulation (DBS) (overall 46 target points) were investigated. The target point of the electrode was planned stereotactically in combination with a preoperative stereotactic helical computed tomography (CT). A postoperative CT, which was carried out still in the operating room while the patient had the stereotactic frame on the head, was performed in order to control the position of the electrodes in relation to the previously planned target point. The position of the four electrode contacts was measured according to the Talairach space (AC-PC line) and compared with the coordinates of the planned target point. The mean spatial distance of planned target perpendicular to the electrode was 1.32+/-0.75mm. These results show the high accuracy of stereotactic implantation of DBS electrodes assisted by pre- and postoperative image fusion with computed tomography (CT).

PMID: 18328766 [PubMed - as supplied by publisher]

Problems in the Pediatric field


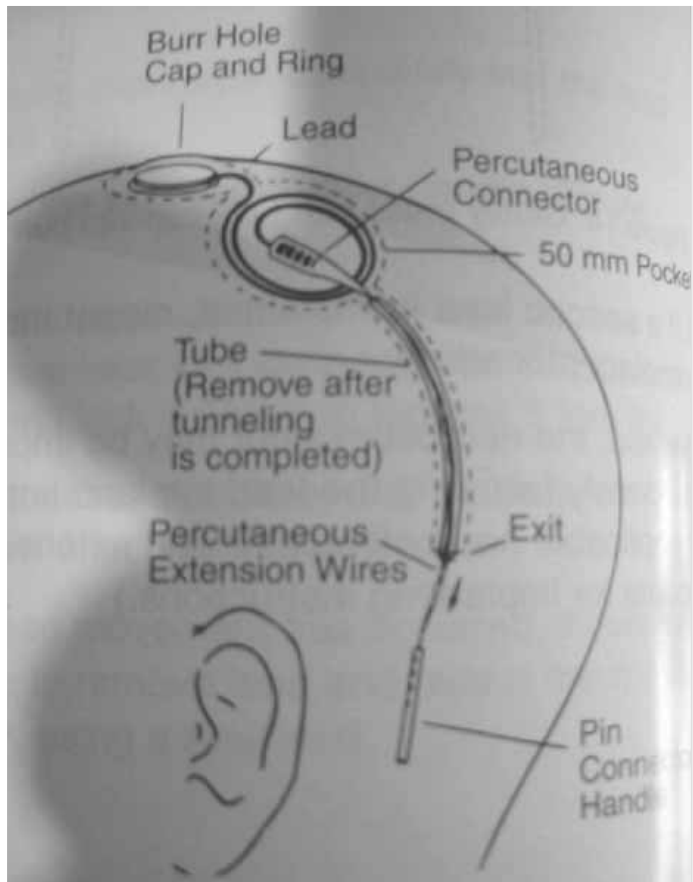
Surgical technique

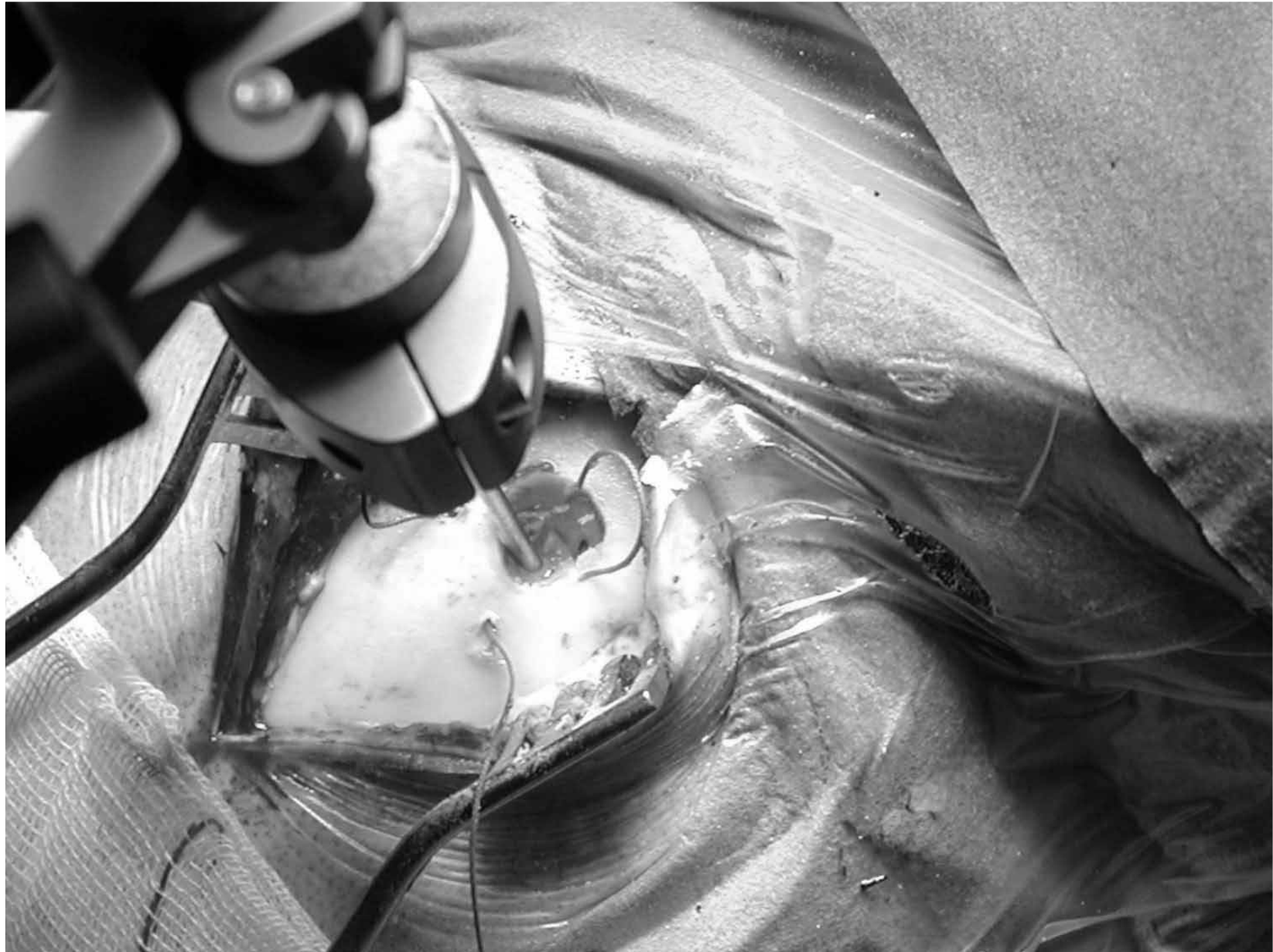- MER disturbed by GA and not possible to detect DBS visual and side effects except with VEP
- early MR control (Coubes' protocol) or intra-op CT or MR
- 4-contacts macro-electrode 3 mm down the optic tract (head growth till 3-6 yrs)

Problems in the Pediatric field

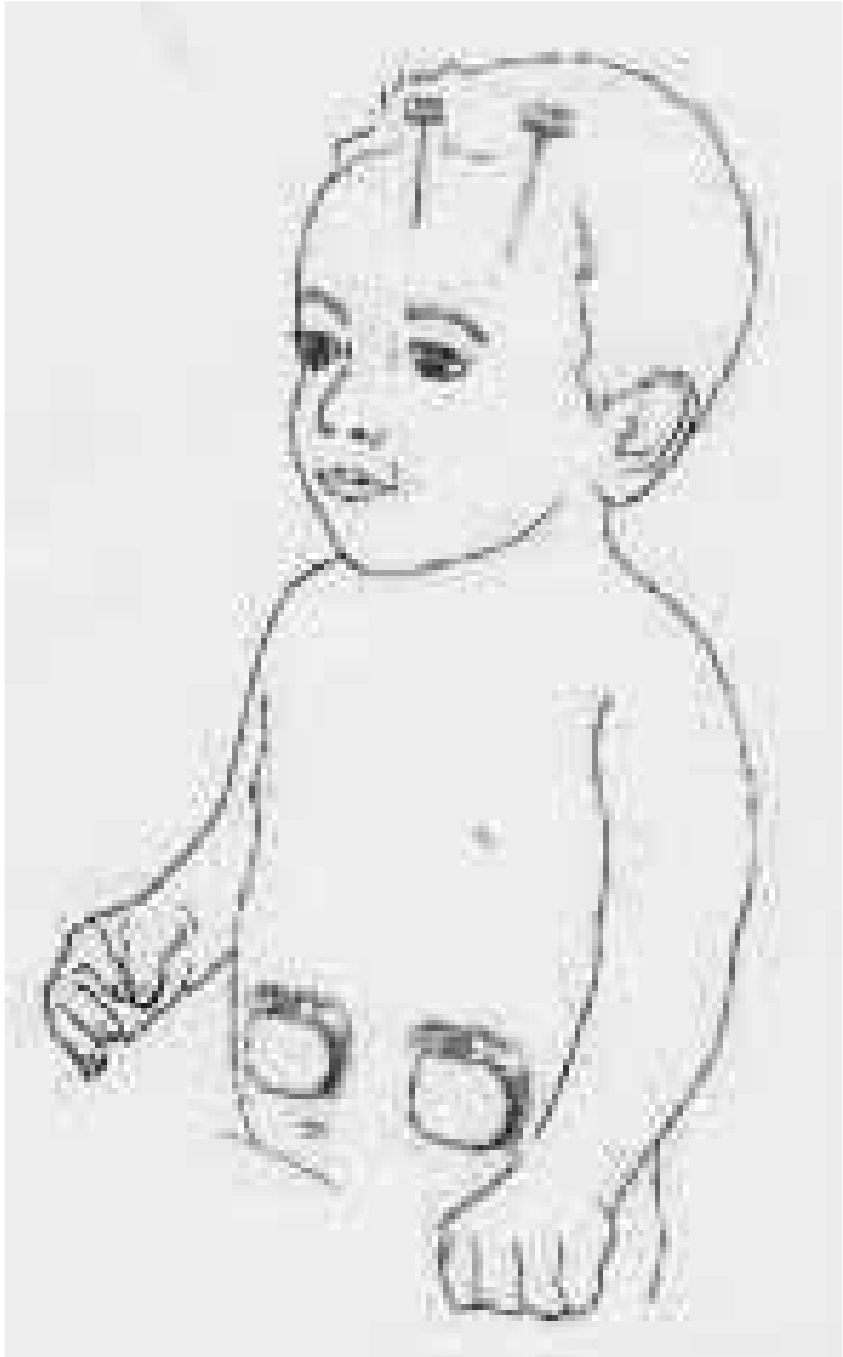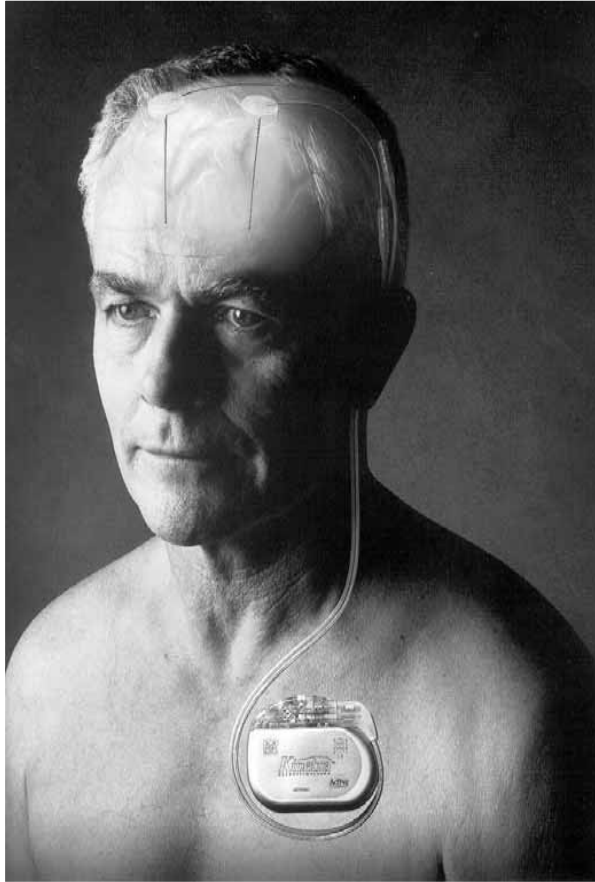
Surgical technique

- surgical morbidity (0-3%) similar to adult but more frequently due to skin reactions to device than surgery itself
- device fixation to the head
- IPG pocket into abdomen for thicker skin and fat; cable length at least 90 cm





Michele Cavallo's technique



courtesy of Pr Coubes
ECMT Course – Montpellier, 2006

Problems in the Pediatric field

Follow-up

- length and head growth
- no effects on endocrine system
- contact sport (....same problems for VP shunting in hydrocephalus....perhaps not true !)
- battery replacement

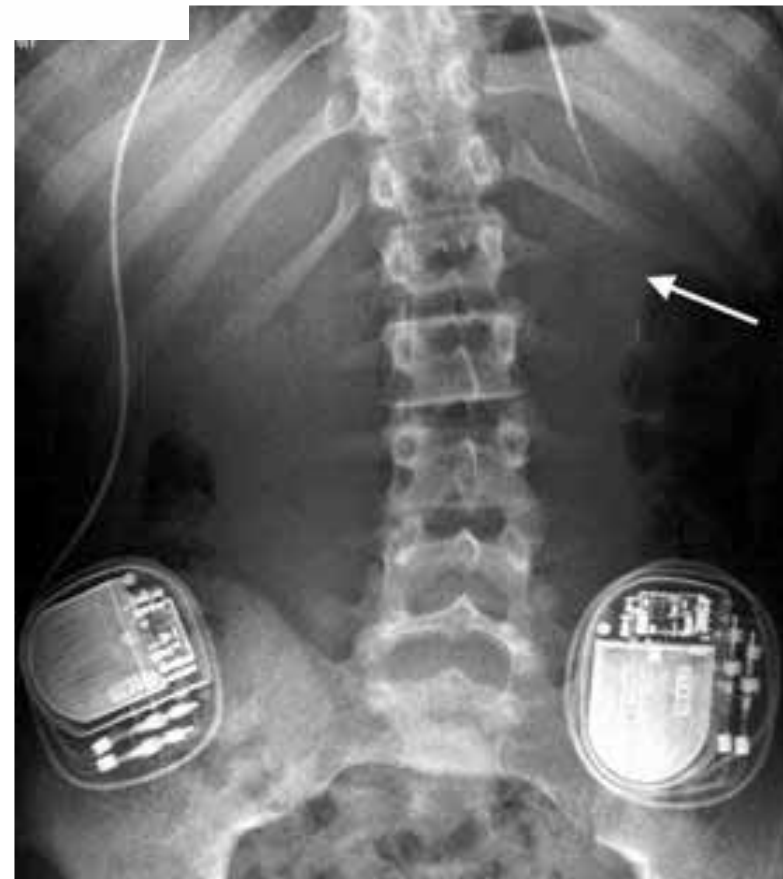
Increased risk of lead fracture and migration in dystonia compared with other movement disorders following deep brain stimulation.

Yianni J, Nandi D, Shad A, Bain P, Gregory R, Aziz T.

The Oxford Movement Disorder Group, Department of Neurological Surgery, The Radcliffe Infirmary, Oxford OX2 6HE, UK.

Deep brain stimulation (DBS) therapy is a continually expanding field in the functional neurosurgical treatment of movement disorders. However, the occurrence of adverse events related to implanted hardware cannot be overlooked. We report on a specific feature noted in our experience of DBS-related complications. From 1998 until present we have found an overall rate of 5.3% of DBS electrode lead dysfunction (out of 133 patients) in our series (slipped leads 2.3%, lead fracture 3.8%). Interestingly, all of these failures occurred in dystonia patients (18.4% of all dystonia patients and 9.2% of all electrodes). We postulate on mechanisms that may explain why these complications predominate in this group of patients.

PMD: 14975410 [PubMed - indexed for MEDLINE]

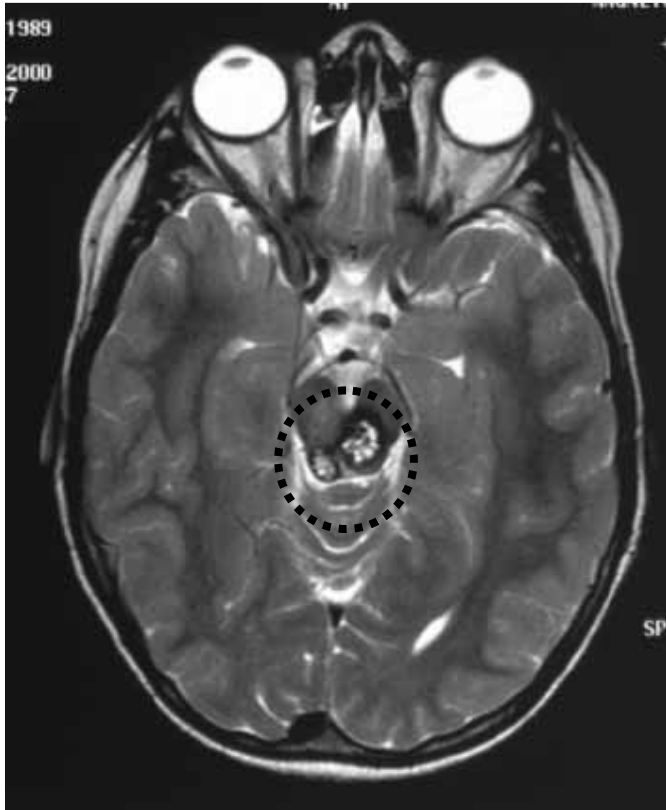

courtesy of Pr Coubes

ECMT Course – Montpellier, 2006

Secondary dystonia: never surgery ?

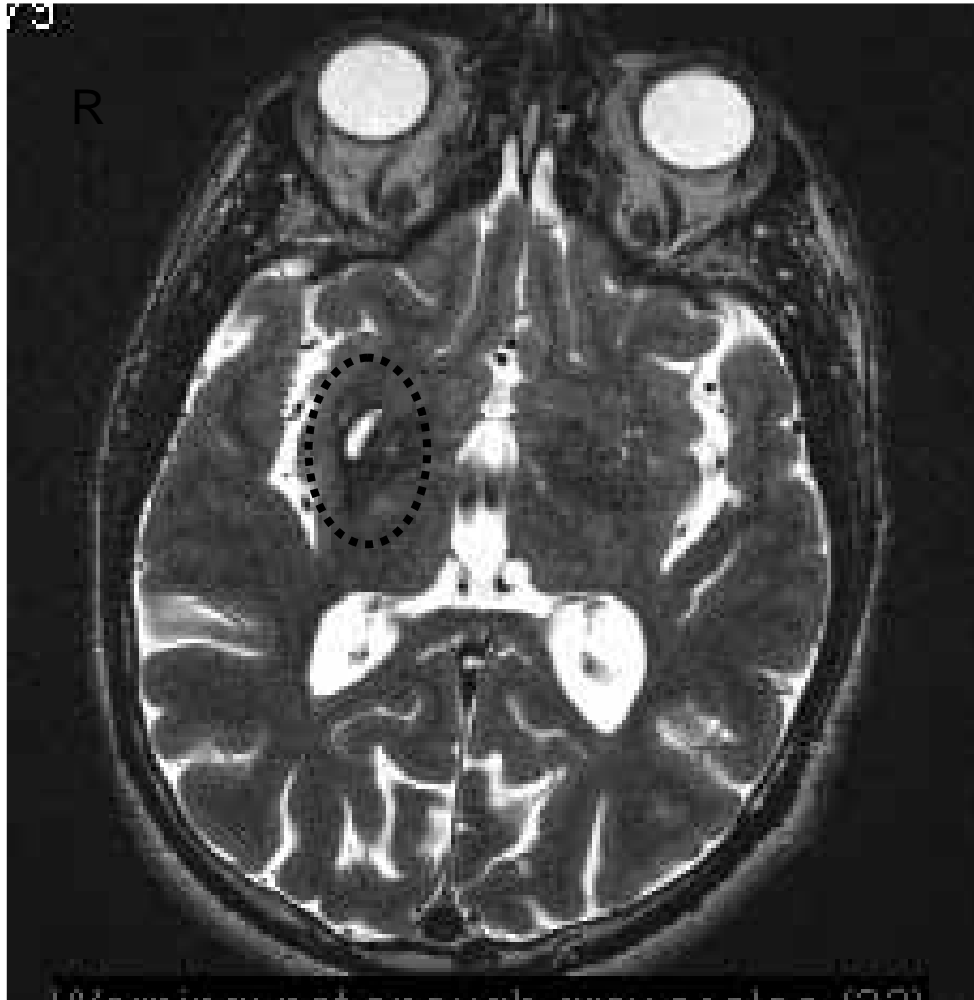- more frequent than primary dystonia (80%)
- 30-40% improvement in literature
- unpredictable results does not mean no results
- wide range of secondary and mixed dystonia
- more damage to sensori-motor pathway (VPL-Gpi)
- different targets along with Gpi (Vim, Voa)
- possible combination with ITB and BoTox



VM, male, 18 yrs. Brainstem cavernoma operated on at 12 yrs old

Secondary dystono-diskinetic syndrome one year after surgery

?



DG, male, 20 yrs. Rt basal ganglia stroke at 6 yrs

Secondary dystono-diskinetic syndrome + tremor in follow-up

?

Conclusions

- heterogeneity and rarity of movement disorders in the developing age
- avoid rigid patient selection → don't be a taliban !
- right technique according to individual child's features and surgeon's experience
- DBS and not lesional surgery is better whenever and as soon as possible
- pediatric multidisciplinary team is better so.....

.....let's stimulate all together !

